

## Mounier Kuhn Syndrome

*Silvio Stomeo*<sup>1</sup>

<sup>1</sup> Specialista in Malattie dell'apparato respiratorio e Direttore del Servizio di Broncologia del P.O. A. Galateo ASL Lecce.

**Corresponding author:** Silvio Stomeo  
stomeo.silvio@libero.it

### Abstract

Mounier Kuhn syndrome or tracheobronchomegaly is characterized by a marked dilatation of the trachea and main bronchi that can extend to the periphery of the lungs. Dilation is due to an alteration of the cartilaginous and membranous structure of the trachea and bronchi. It is a pathology much more frequent in men. The aetiology is unclear. The clinical case in question concerns a 67-year-old man who has reported recurrent episodes of bronchopulmonary infections and hemoptysis, after undergoing instrumental investigations (fibrobronchoscopy and chest CT), the diagnosis of Tracheobronchomegaly or Mounier Kuhn syndrome was formulated.

**Keywords:** Tracheobronchomegaly, bronchiectasis, diverticula, clearance, chronic inflammation, atrophy, connective tissue disorders (Ehlers-Danlos syndrome and Marfan syndrome)

### I. Introduction

Mounier Kuhn syndrome or idiopathic tracheobronchomegaly is a rare disease first diagnosed in 1932. About 300 cases have been described in the literature in the world. The clinical symptomatology is common to that of COPD and bronchiectasis, so it is assumed that the incidence of the disease is greater because it is undiagnosed (underestimated). This condition occurs more frequently in males than in females. The disease is characterized by an abnormal dilatation of the tracheobronchial tree, which can extend all the way from the larynx to the periphery of the lung. The tracheobronchial mucosa has a chronic inflammation and a remarkable atrophy that determines the alteration of the mucociliary system, this favors a variation of the clearance of the secretions, which, together with an ineffective mechanism of cough, as in bronchomalacia, facilitates the stagnation of secretions and it is responsible for recurrent infections (pneumonia), bronchiectasis and diverticula mainly of the pars membranacea). Although the aetiology is not clear, its association with connective tissue diseases, such as Ehlers-Danlos syndrome, Marfan syndrome and cutis laxa, suggest an underlying defect in elastic tis-

sue. From the anatomopathological point of view, both the cartilaginous and membranous portion of the trachea and bronchi are involved, both presenting a thin muscular and elastic atrophic tissue. Therefore, the tracheobronchial airways are dilated during inspiration and collapsed during expiration. The disease may present at all ages but is usually diagnosed in the third or fourth decade of life in adults with recurrent bronchopneumonia. The diagnosis can be made thanks to the use of chest CT and fibrobronchoscopy. The treatment of this pathology is symptomatic. Chest physiotherapy can be proposed to improve mucociliary clearance and antibiotic therapy to treat lung infections that can sometimes lead to the appearance of bronchial suppuration with respiratory failure. Differential diagnosis includes bronchitis, chronic obstructive pulmonary disease, bronchiectasis, William Campbell's syndrome or tracheobronchomalacia.

In normal conditions, the dimensions of the trachea are in men the following: transverse portion > 25 mm, sagittal portion > 27 mm. In women, transverse portion > 21mm and in sagittal portion > 23mm. For the bronchi, in women the measurements are linked to right > 19.8

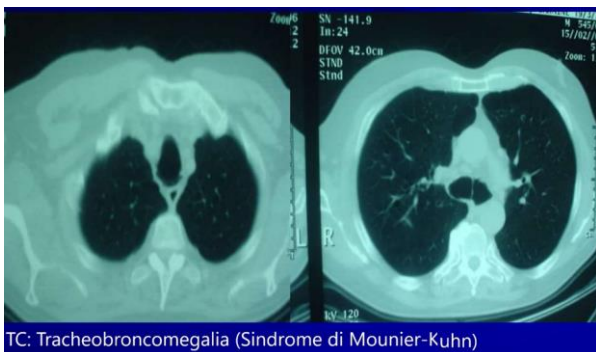
mm and to the left > 17.4 mm; for men on the right > 21, on the left > 18.

## II. Clinical Case

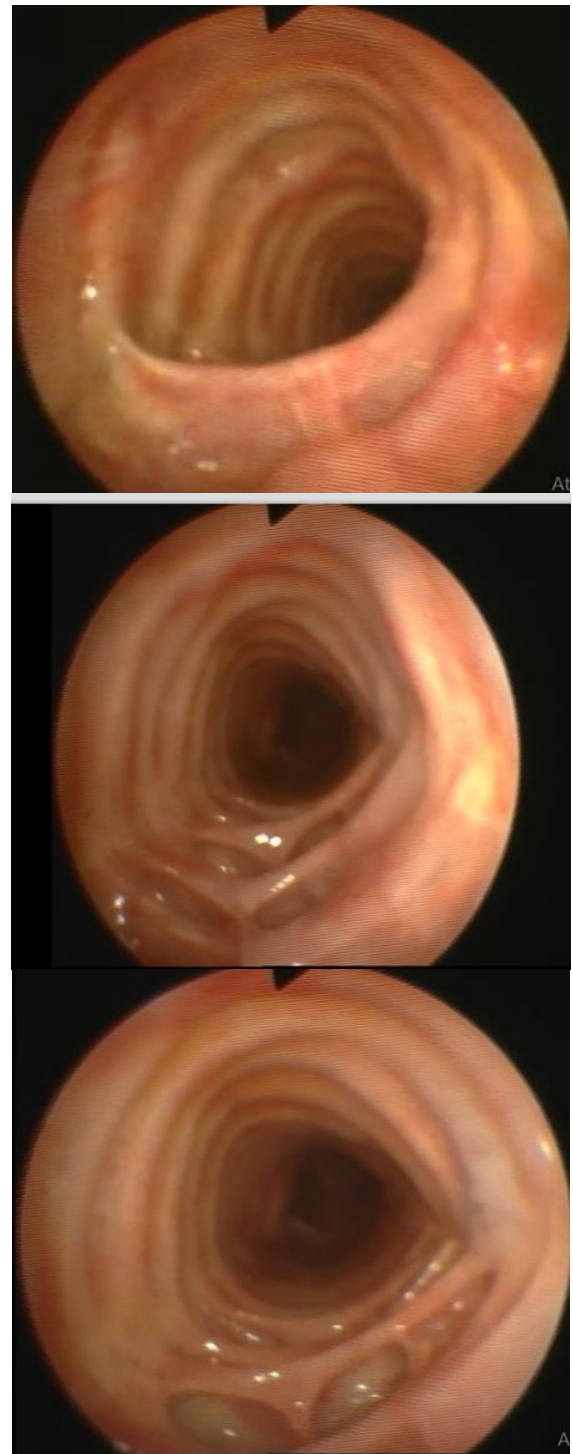
He came to my observation at the BRONCOLOGIA service, of the Galateo Hospital of San Cesario in Lecce, a man of 67 years in fair general conditions, non-smoker, repeatedly hospitalized at the above described hospital for recurrent bronchial infections in subject who had been diagnosed with chronic obstructive pulmonary disease (COPD). The symptomatology was characterized by a persistent cough with low emission of mucopurulent sputum, mild dyspnea on exertion, hemoptysis. Respiratory function tests show only a modest functional deficit of respiratory function parameters (FEV1, FVC and FEV1/FVC).

Blood gas analysis showed a slight reduction of pO<sub>2</sub> (76.5 mmHg). Laboratory tests showed an increase in white blood cells (WBC 17,580).

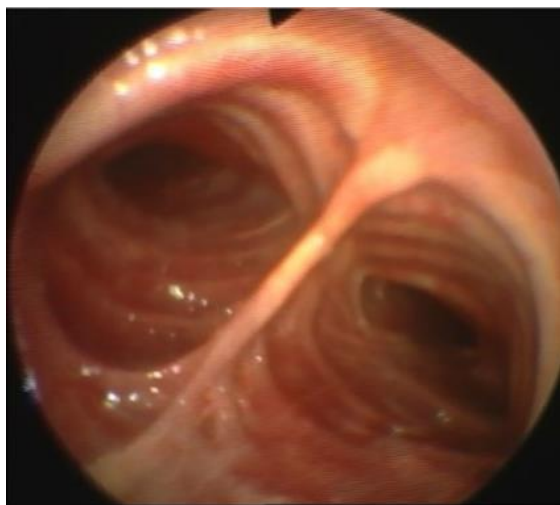The fibrobroncoscopic examination allowed to find a marked amplitude of the trachea (greater than 30 mm in diameter) and of the main bronchi (greater than 25 mm in diameter) where there was a partially pale, thin (atrophic) mucosa, in part, congested with presence of bronchiectasis, diverticula of the pars membranacea of the trachea and immediately after the entrance of the left main bronchus, abundant mucopurulent secretions. The CT scan of the thorax confirmed the increase in amplitude of the trachea and main bronchi.



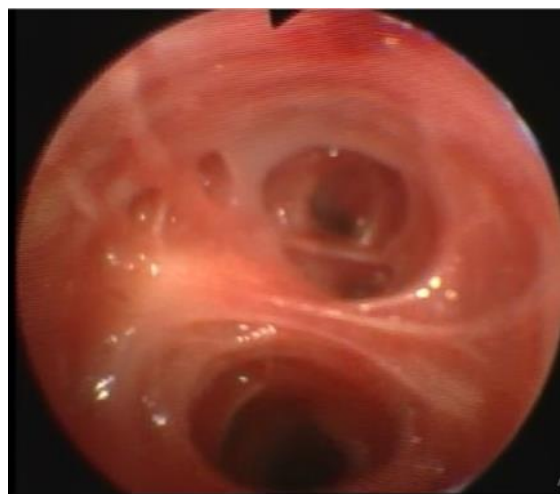**Figure 1.** Abnormal dilatation of the trachea and main bronchi



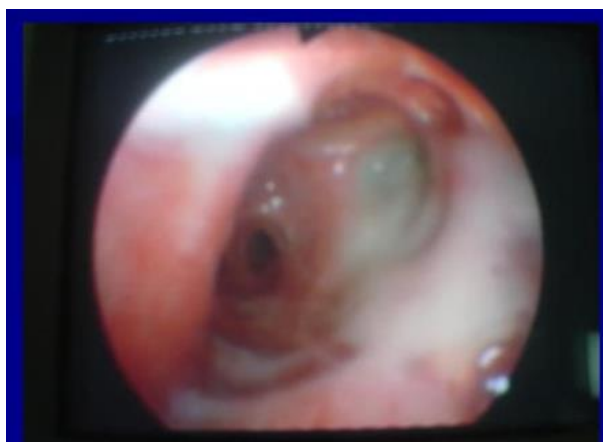**Figure 1.** Tracheomegaly with pars membranacea diverticula



**Figure 2.** Bronchomegaly with diverticula located on the posterior wall of the left main bronchus immediately after the carina.



**Figure 3.** Peripheral bronchiectasis



**Figure 4.** Mucopurulent secretions present in the subsegmentary bronchi

### III. Conclusions and considerations

The symptomatology of the above described pathology is generally not distinguishable from that of chronic obstructive bronchitis and from bronchiectasis. However, recurrent infections and the presence of a prolonged cough and a loud and hard sound during the auscultation of the chest of patients who complain of an inability to expectorate the secretions should make the diagnosis suspect. Pulmonary function tests typically show a reduction in expiratory flows and a widening of dead space. This pathology cannot be treated surgically due to its extension. However, a symptomatic treatment can be performed (fibrobronchoscopy to aspirate secretions, antibiotic therapy to treat infections, chest physiotherapy and postural drainage to improve the mucociliary clearance).

### References

- Sindrome di Mounier- Kuhn o Tracheobronchomegalia - [www.imalatiinvisibili.it](http://www.imalatiinvisibili.it)
- Diagnosi delle Malattie del Torace (2001) IV Edizione capitolo X Malattie delle vie respiratorie- Tracheobronchomegalia (Fraser-Parè)
- La trachea Giovanni Piacenza (1992) Capitolo V- Tracheobronchomegalia sez. IV- tracheobronchomegalia (sindrome di Mounier-Kuhn)
- Malattie del torace Diagnostica per Immagini e valutazione clinica Fraser-Parè (2006) capitolo XV patologia delle vie aeree- Tracheobronchomegalia.
- La radiografia del mese CHEST edizione italiana (2002), [www.midiaonline.it](http://www.midiaonline.it)
- Bateson, Eric M., and Michael Woo-Ming (1973). "Tracheobronchomegaly." *Clinical Radiology* 24 (3): 354–58.
- Udeaya B.S.Prakash. (1995). Broncoscopia

